DIESEL EXHAUST IMPACTS AND RISK ESTIMATES: PERSPECTIVES FROM TOXICOLOGY

Joe L. Mauderly

Lovelace
Respiratory Research Institute

Lovelace Respiratory Research Institute
Albuquerque, New Mexico

THE RAT LUNG TUMOR RESPONSE TO DIESEL EXHAUST DOES NOT PREDICT HUMAN LUNG CANCER RISK

- Not predictive for other animal species
- Not chemical carcinogenesis
- Cellular response resulting in rat tumors does not model human response

3639W-1

LONG-TERM EXPOSURE OF RODENTS TO DIESEL EXHAUST

Subjects

- Male and female F344 rats and CD-1 mice

Exhaust

- 1980 GM 5.7L engine on urban cycle
- D-2 certification fuel (30% aromatics, 0.3% sulfur)

Exposures

- 7 hr/day x 5 days/wk x 30 mo
- 350, 3470, 7080 μg soot/m^3

Evaluations

- Carcinogenicity
- Non-cancer lung responses

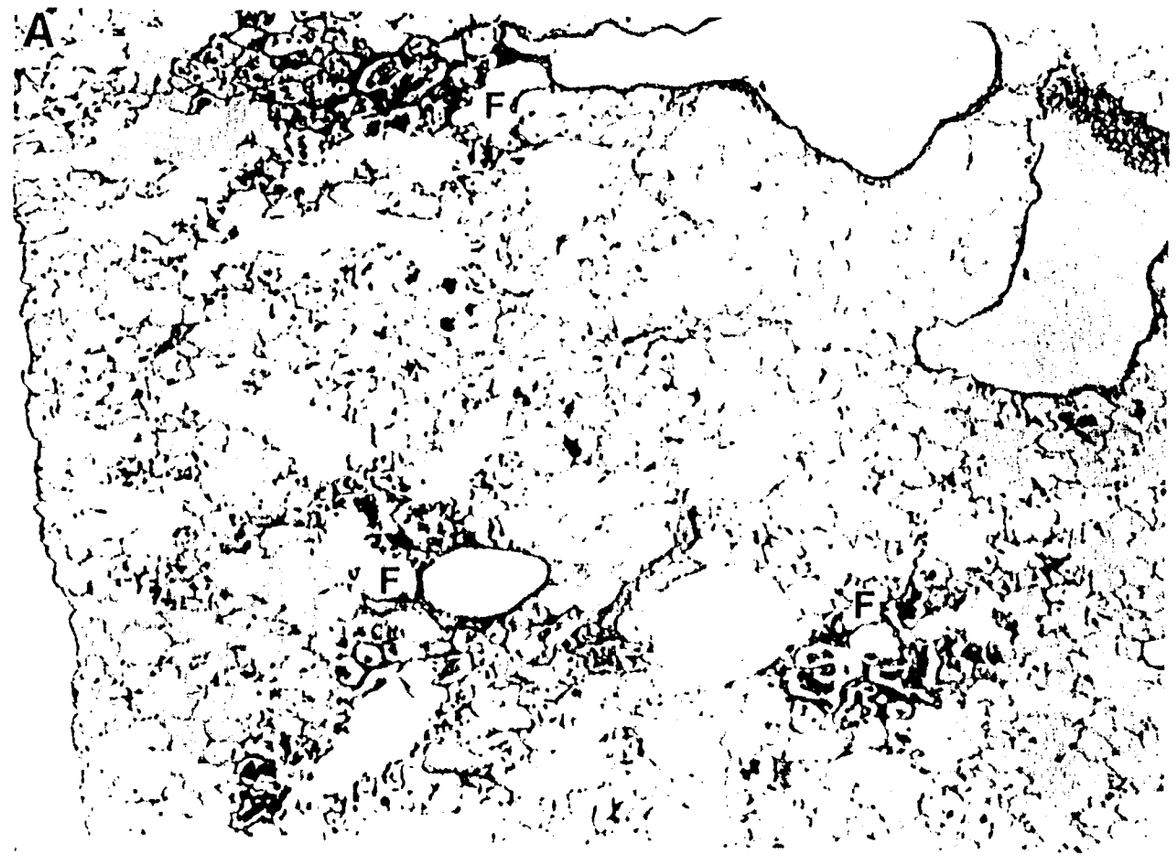

FIGURE 9. Light photomicrographs, shown at identical magnification, of the lungs of F344 rats (A) after exposure 7 h/day, 5 days/wk for 18 mo to diesel exhaust at 7080 μg soot/m^3. The size-adjusted lung burden of soot was similar in both species. Foci (F) of soot-laden macrophages and thickened alveolar septae can be seen in the rat lung. Soot-laden macrophages are more evenly dispersed in the mouse lung, and foci of tissue response like those seen in the rat are not apparent.

B

FIGURE 9. (*Continued*) Light photomicrographs, shown at identical magnification, of the lungs of CD-1 mice (B) after exposure 7 h/day, 5 days/wk for 18 mo to diesel exhaust at 7080 μg soot/m^3. The size-adjusted lung burden of soot was similar in both species. Foci (F) of soot-laden macrophages and thickened alveolar septae can be seen in the rat lung. Soot-laden macrophages are more evenly dispersed in the mouse lung, and foci of tissue response like those seen in the rat are not apparent.

EPITHELIAL PROLIFERATION AFTER 18 MO. EXPOSURE TO DIESEL EXHAUST AT 7.1 mg/m^3 SOOT

(Mauderly et. al., 1983)

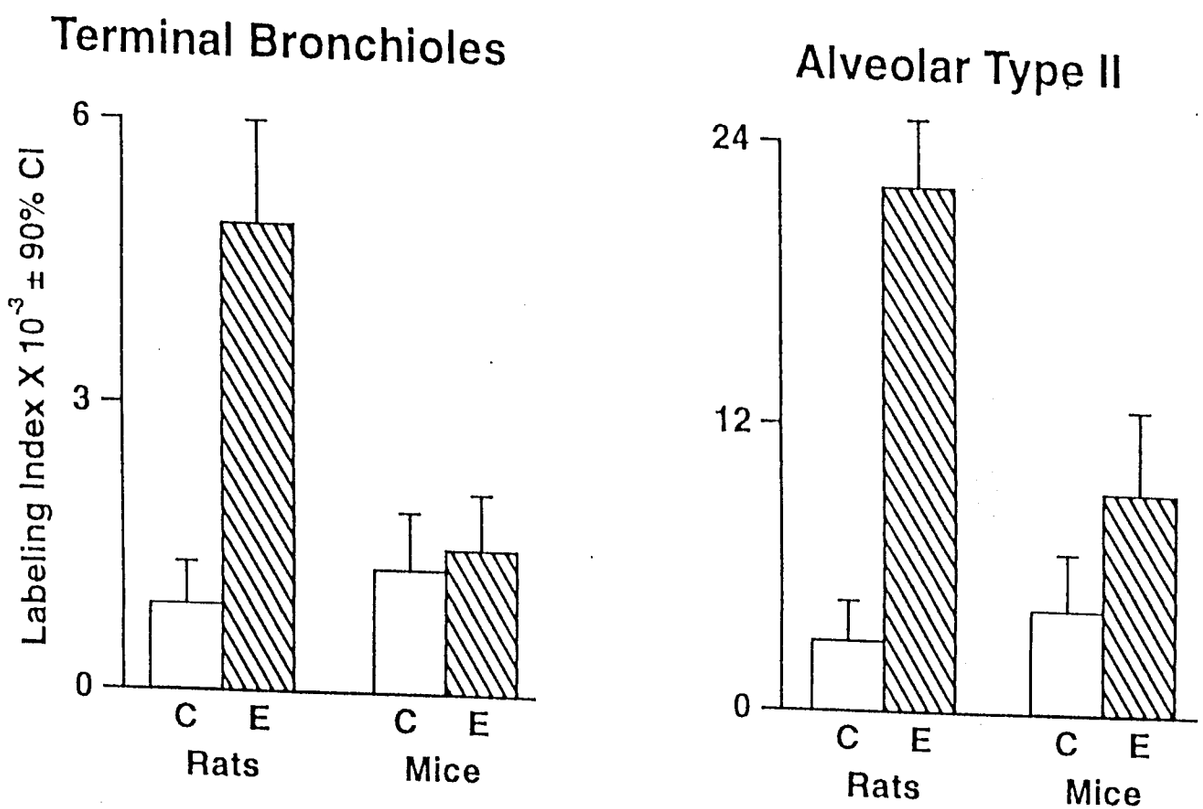

RAT vs. MOUSE RESPONSES TO 18-MONTH EXPOSURE TO DIESEL EXHAUST

(Henderson *et al.*, 1988)

- M + F F344 rats and CD-1 mice exposed 7 hr/day, 5 days/wk at 3.5 or 7.1 mg/m^3

	Mouse/Rat	
$mg \cdot hr \cdot m^{-3}/wk$ =	123	249
Lung		
mg soot/g lung	1.6	1.3
Lung weight	1.5	1.4
Total lung collagen	1.4	1.3
Reduced glutathione	2.1	3.1
Bronchoalveolar lavage		
Neutrophils	0.3	0.3
Lactate dehydrogenase	0.9	0.5
Hydroxyproline	1.5	0.7
Protein	1.8	1.2
Glutathione reductase	1.8	1.2
Reduced glutathione	1.6	1.7

LUNG TUMORS IN RATS AND MICE EXPOSED TO DIESEL EXHAUST

(Mauderly *et al.*, 1987)

- F344/Crl rats (n = 108-119/sex) and CD-1 mice (n = 59-104/sex)
- Exposed 7 h/d, 5 d/wk from 17 wks to death or 30 mo
- Median survival (mo) not affected by exposure

% With Adenomas or Carcinomas

mg/m^3	Rats		Mice	
	M	F	M	F
0	2 (26.4)	0 (27.1)	13 (14.1)	16 (16.4)
0.35	1	2	6	21
3.5	4	2	8	10
7.1	9 (26.2)	9 (28.1)	6 (14.5)	9 (16.8)

FIGURE 8. Light photomicrograph of a squamous cyst, in this case, located just below the pleural surface (top). These lesions consist of accumulations of keratin surrounded by flattened, well-differentiated epithelial cells at the periphery. The lesion pushes aside alveoli as it grows but does not invade adjacent structures. Occasionally, epithelial cells at the edge of the cysts form squamous-cell carcinomas, but in the absence of this, the cyst is not considered a neoplasm.

30-MONTH EXPOSURE OF RATS TO DIESEL EXHAUST AT A SOOT LEVEL OF 350 $\mu g/m^3$ DID NOT CAUSE:

Focal accumulation of soot

Reduced particle clearance

Inflammation

Epithelial proliferation

Fibrosis

Tumors

NON-FIBER SOLID PARTICLES CARCINOGENIC IN RATS EXPOSED HEAVILY BY INHALATION OR INSTILLATION

Activated carbon
Antimony ore
Antimony trioxide
Carbon black
Coal dust
Diesel soot
Hematite
Magnetite
Nickel oxide
Oil shale dust

Quartz
Talc
Titanium dioxide
Volcanic ash

NONFIBROUS PARTICLES CAUSING LUNG TUMORS IN RATS BY INHALATION, BUT NOT IN MICE

	Hamster
Cadmium chloride	—
Cadmium sulfate	—
Cadmium sulfide	—
Carbon black	ND
Nickel metal	ND
Nickel oxide	—
Nickel subsulfide	—
Silica (crystalline)	ND
Talc (asbestos-free)	—
Titanium dioxide	ND

PULMONARY CARCINOGENICITY OF INHALED DIESEL EXHAUST AND CARBON BLACK IN RATS

- 105 M and 105 F F344/N rats, 8 wk old at start
- Exposed to DE or CB 16 h/d x 5 d/wk x 24 mo
- Evaluated: body weight, survival, particle lung burdens, bronchoalveolar lavage, particle clearance, histopathology, tumor growth in athymic mice
- Groups:

	Particle Concentration (mg/m^3)
HDE	6.33
LDE	2.44
HCB	6.55
LCB	2.46
C	0.05

RESULTS

- High levels caused slight reductions in body wt. and survival
- Particle clearance impaired in all groups by 3 mo
- Progressive, dose-related lung inflammation, epithelial proliferation, and fibrosis in all groups

	Lung Burden (mg at 23 mo)	% With M + B Lung Tumors		
		M	F	M + F
HDE	85	9	27	17.9
LDE	41	5	8	6.2
HCB	39	4	27	15.2
LCB	21	2	8	4.7
C	0	3	0	1.4

CUMULATIVE EXPOSURE vs TUMOR RESPONSE

(Heinrich, 1994)

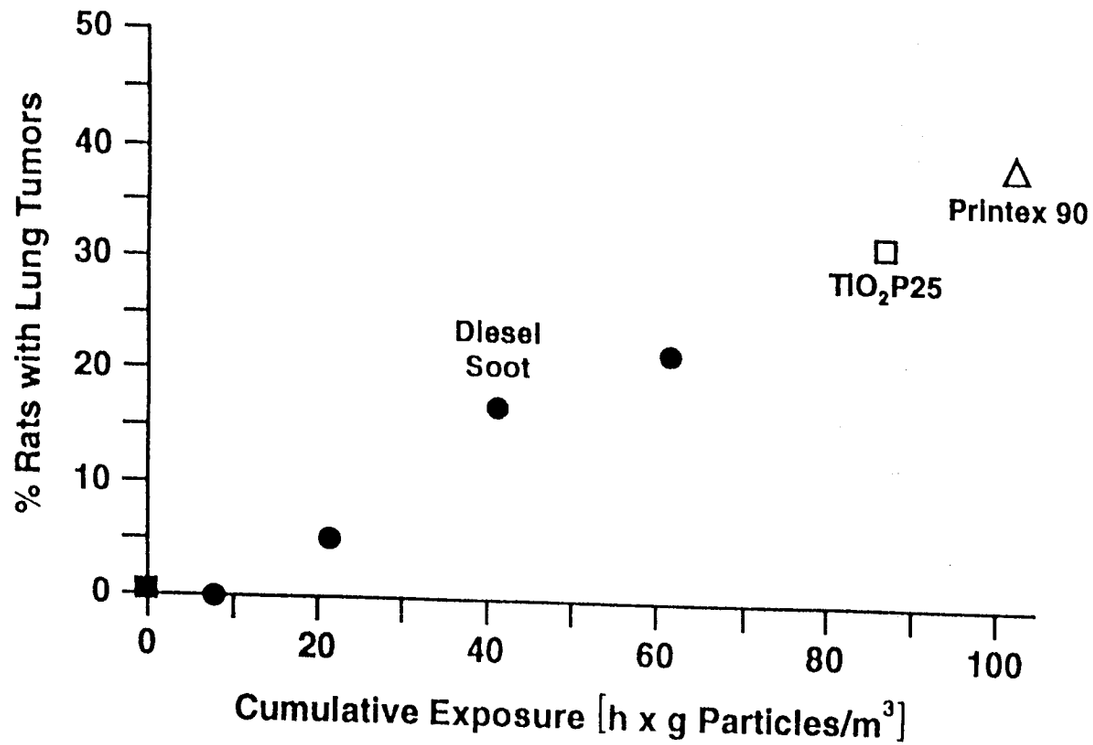

THE QUESTION IS RELEVANCE TO HUMANS

≠

≟

≠

≟

LUNG RESPONSES OF RATS vs MONKEYS

(Nikula et al., 1997)

- Lungs from NIOSH study (Lewis et al., 1989)
- F344 rats and cynomolgus monkeys
- Exposed 6 hr/d x 5 d/wk x 2 yr

  2 mg/m^3 diesel exhaust soot
  2 mg/m^3 respirable coal dust
  1 mg/m^3 DE + 1 mg/m^3 CD

- Detailed evaluation of:

  Particle location
  Cellular response



FIG. 1. Overview of particulate material in exposed rats and monkeys. (A) DECD rat. The particulate material is primarily within intralumenal macrophages in centriacinar alveoli. Arrowheads, small macrophages with few particles; arrows, large macrophages or macrophage aggregates with many particles; AD, lumen of alveolar duct. ×200. (B) DE rat. Soot primarily within intralumenal macrophages in alveoli adjacent to the pleura. Soot also located within the pleura in this region (open arrow). Chronic inflammation with mixed neutrophilic and mononuclear cells (arrows) and cholesterol clefts in multinucleated giant cells (arrowheads). ×150. (C) DE monkey. Soot within macrophages in alveolar lumens (arrows) and alveolar septa (arrowheads). AD, lumen of alveolar duct. ×200. (D) DECD monkey. Particulate material in the interstitium of a respiratory bronchiole (RB, arrow) and the alveolar septa (arrowheads). AD, lumen of alveolar duct. ×75.

EXPOSURE RATE-TUMOR RESPONSE RELATIONSHIP FOR DIESEL EXHAUST INHALED CHRONICALLY BY RATS

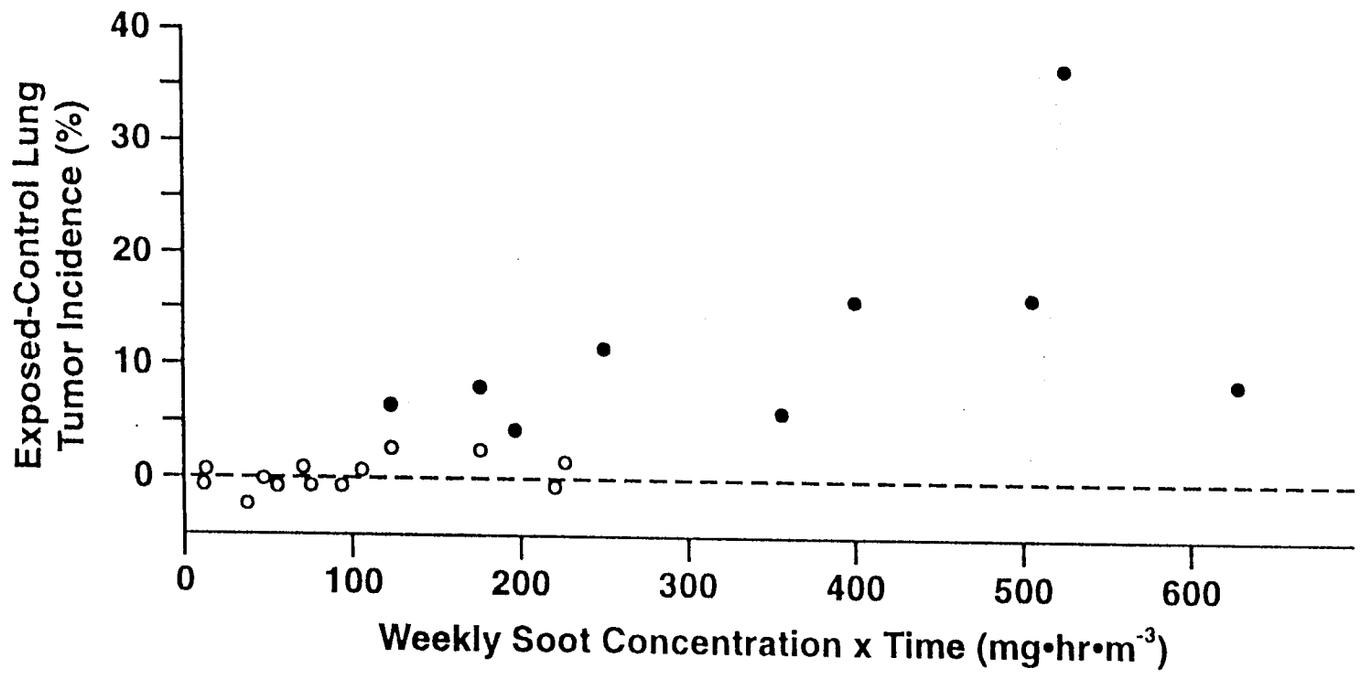

3545-1

SUMMARY

1. Diesel exhaust contains toxic, mutagenic, and carcinogenic agents

2. The lung tumor response of rats to diesel soot should not be used for quantitative estimates of human lung cancer risk.

3. The irrelevance of the rat response does not prove that there is not cancer risk for humans.

4. The toxicological evidence suggests that diesel exhaust probably presents no unique health risk, only that due to its contribution of gases, vapors, particles, and organics to the atmosphere.